

MRI IN HYPERACUTE STROKE: EARLY EXPERIENCE

Mohd Fandi Al Khafiz Kamis¹, Mohd Naim Mohd Yaakob¹, Ezamin Abdul Rahim¹, Hasyima Abu Hassan¹, Abdul Hanif Khan Yusof Khan², Aizad Azahar³, Noor Hafizah Abdul Salim^{4,5}, Nabila Hanem Arshad¹, Ahmad Sobri Muda¹

¹Department of Radiology, Faculty of Medicine and Health Sciences, Hospital Pengajar Universiti Putra Malaysia, Universiti Putra Malaysia, 43400 Serdang, Malaysia

²Department of Neurology, Faculty of Medicine and Health Sciences, Hospital Pengajar Universiti Putra Malaysia, Universiti Putra Malaysia, 43400 Serdang, Malaysia

³Department of Anesthesia and Intensive Care, Faculty of Medicine and Health Sciences, Hospital Pengajar Universiti Putra Malaysia, Universiti Putra Malaysia, 43400 Serdang, Malaysia

⁴Department of Emergency Medicine, Faculty of Medicine and Health Sciences, Hospital Pengajar Universiti Putra Malaysia, Universiti Putra Malaysia, 43400 Serdang, Malaysia

⁵Department of Medicine, Faculty of Medicine and Health Sciences, Hospital Pengajar Universiti Putra Malaysia, Universiti Putra Malaysia, 43400 Serdang, Malaysia

*Corresponding author:

Ahmad Sobri Muda, Department of Radiology, Faculty of Medicine and Health Sciences, Hospital Pengajar Universiti Putra Malaysia, Universiti Putra Malaysia, 43400 Serdang, Malaysia

Email: asobri@upm.edu.my

DOI: <https://doi.org/10.32896/cvns.v5n2.1-8>

Received: 27.01.2023

Revised: 15.06.2023

Accepted: 20.06.2023

Published: 30.06.2023

ABSTRACT:

Background: In many institutions, computed tomography is the preferred neuroimaging modality for acute stroke (CT). MRI, on the other hand, is more sensitive in detecting infarct core. We present our early experience adopting MRI-first policy, using Putra Acute Stroke Protocol with 8-minute first 3 sequences, for hyperacute stroke.

Methods: We retrospectively reviewed our early 6 months experience between June until Dec 2020. All hyperacute stroke cases who had MRI first and the door to needle (DTN) were evaluated.

Results: There were total of 124 cases with 11 haemorrhagic stroke (8.9%) and 6 cases stroke mimics (4%). There were total of 105 cases of acute stroke, who had MRI first, where, 18 were thrombolysed (17.1%) while 8 cases had thrombectomy (7.6%). Fourteen were thrombolysed within 60 minutes (77.8%). DTN time range between 6 to 78 minutes with total accumulated time of 716 minutes, giving an average DTN of 42 minutes.

Conclusion: Our experience shows there is no significant overall delay in DTN. MRI-first policy, adopting Putra Acute Stroke Protocol, helps to achieve higher percentage of thrombolysis rate. The stroke mimics and haemorrhagic stroke were excluded effectively.

MeSH Keywords: Stroke, Acute, Magnetic Resonance Imaging, MRI, Putra Acute Stroke Protocol

INTRODUCTION:

While CT is employed as the first-choice neuroimaging for acute stroke in numerous institutions, early infarct signs on CT can be indistinct and difficult to be noticed. Magnetic resonance imaging (MRI), particularly diffusion-weighted imaging has been proven to be significantly more sensitive than CT in identifying infarct core with superior correlation to the infarct volume [1,2]. More specific tissue information from imaging is required in hyperacute stroke due to recent doubts regarding the current understanding of the ischemic core [3].

CT is accepted as the imaging modality of choice to rule out haemorrhage in haemorrhagic stroke. However, MRI is shown to give similar accuracy compared to CT [4]. Newly developed sequences like susceptible weighted imaging (SWI) proved to be more sensitive compared to CT in detecting haemorrhage [5]. The information provided by MRI in hyperacute stroke is notably more valuable than CT. However, it does come with many drawbacks such as perceived higher cost, longer scanning time, and lack of availability. Although, in some works, door-to-needle (DTN) time was found to not be compromised by adopting MRI in hyperacute stroke [6-8]. The centre of this article's work is a newly established teaching hospital that began operations in April 2020. The stroke services comprise multidisciplinary teams under the banner of the Registry of Stroke Care Quality (RES-Q) [9]. We present our early experience adopting MRI first for hyperacute stroke with acceptable DTN.

MATERIALS AND METHODS:

We retrospectively reviewed our early 6 months experience between June until Dec 2020. All presentations, which triggered acute stroke code, were evaluated. Subjects with acute stroke who had MRI first were selected. All MRI

cases are performed with Philips Ingenia 3.0 Tesla. In our centre, we adopt Putra Acute Stroke Protocol for hyperacute cases, which takes 8 min duration for the initial three sequences of MR protocol. The protocol begins with a Diffusion Weighted Imaging (DWI), which is subsequently followed by fluid-attenuated inversion recovery (FLAIR) and ends with magnetic resonance angiography (MRA) as shown in Table 1 [10]. Imaging is then paused for the treatment decision. If it was decided for intravenous thrombolysis (IVT), the bolus dose is given immediately in the magnetic resonance (MR) suite, followed by infusion dose, according to the IVT protocols while the MRI examination continues (Fig. 1). Medical personnel perform closed monitoring of the vitals and intermittent clinical evaluations in the MR suite. In cases decided for mechanical thrombectomy (MT), preparation for the procedure is initiated immediately while the MR scanning will continue without compromising the transfer time to the angiography suite.

If a suspected haemorrhage is noted on the first sequence (DWI), Susceptibility Weighted Imaging (SWI) is applied as the subsequent sequence to confirm the presence of the haemorrhage. All cases of haemorrhagic stroke show an area of hypointensity with surrounding hyperintense rim on DWI (b1000). The haemorrhagic stroke cases are illustrated with a comparison to SWI and CT (Fig. 2). In selected doubtful cases, the treatment decision is decided after extra sequences, for example in stroke mimics or recurrent infarcts.

The doors to needle (DTN) are recorded according to the usual practice. The DTN was reviewed and analysed. The institutional review board has waived the written informed consent.

RESULTS:

Between June to December, there was a total of 124 cases presented to our institutions with acute stroke, triggering stroke code red. There are 11 haemorrhagic strokes (8.9%) while 6 cases were diagnosed as stroke mimics (4%). 2 cases underwent CT first, due to the inability to lie flat in one case and another case is due to the technical problem of the MR scanner. There was a total of 105 cases of acute stroke triggering stroke code red, who had MRI first.

Out of 105 acute stroke patients, 18 were thrombolysed representing a 17.1% thrombolysis rate, while 8 cases had thrombectomy (7.6%). One of the thrombolysed patients had CT first instead of MRI.

Fourteen cases who had MRI-first were thrombolysed within 60 minutes (77.8%), while 3 cases from the MRI group, were thrombolysed beyond 60 minutes. Two of the cases deteriorated and needing intubation, thus delaying the IVT to 66 minutes and 78 minutes. The DTN range was between 6 to 78 minutes with a total time of 716 minutes for 17 IVT cases, giving the average DTN of 42 minutes.

DISCUSSION:

To differentiate differences between acute stroke subtypes for treatment eligibility assessment, neuroimaging plays a major role as a biomarker. Early identification of intracranial hemorrhage, stroke mimics, and capability to identify viable tissues are of utmost importance in the management of hyperacute stroke. Goyal et al. have shown door to reperfusion time is reduced greatly by applying MRI-first policy which makes it achievable in a tertiary general academic teaching hospital [3]. There is an increasing number of facilities worldwide adopting MRI-first policy for acute stroke [4]. Feasibility and safety with an acceptable DTN have been shown from various works concerning MRI-first in acute stroke [5-8]. Thomalla et

al. have shown in 2018, ischemia regions where DWI and FLAIR were adopted presented a functional outcome that was notably better and more intracranial haemorrhages numerically compared to placebo at 90 days [5]. The patients had acute stroke with an unknown onset time, and, DWI and FLAIR mismatched with guided intravenous alteplase.

Currently, our centre adopts Putra Acute Stroke Protocol where the first three sequences consisting of DWI, FLAIR, and MRA took only 8 min to be completed, and treatment can be decided in almost all cases. In suspected haemorrhage on DWI, 2nd sequence is shifted to SWI [10]. Imaging is then paused for the clinical team to decide on the next procedure to be taken from

- 1) Initiation of the intravenous tissue plasminogen activator treatment, and,

- 2) Triggering of the MT preparation. The following sequences will be determined by the clinical indication during the procedure.

Usually this will include arterial spin labelling (ASL), SWI, and, MRA carotid. If contrast was given to the patient, then, contrast MR perfusion and black blood (BB) imaging will be performed.

The adopted protocol, which is facilitated by the tendency to thrombolysed inside the MR suite, allows the clinical team to support the initial decision after the third sequence, and immediately thrombolysed upon decision, thereby reducing DTN time. The majority of current guidelines recommend DTN to be within 60 minutes [6-7]. With average DTN of 42 minutes, in our early experience, adopting MRI-first policy in hyperacute stroke did not significantly delay our acute treatments. MRI gives other numerous advantages with clearer understanding of the tissue status, giving rise to improved patient selection [12-13]. MRI also assists confidently to rule out stroke mimics and avoid unnecessary treatment, which may cause haemorrhagic complications. In our data, the 4% stroke

mimic were diagnosed confidently with MRI, similarly with haemorrhagic stroke were confidently diagnosed where all cases of haemorrhagic stroke show hypointense area in DWI (b1000) with hyperintense rim (Fig. 2).

A rapid MRI protocol must be nearly indistinguishable for a CT scan especially with regards to the turnaround time [1]. A workflow should be designed to reduce the turnaround time for a rapid MRI scan. The duration from triaging and transporting the patients for imaging to interpretation of MR images should be similar to a typical CT exam. This is to ensure acute stroke patients benefit from MR first policy.

CONCLUSION:

Our experience adopting MRI first policy for acute stroke shows no significant overall delay in DTN. While the thrombolysis rate is higher with effective exclusion of stroke mimics.

DATA AVAILABILITY:

Further information regarding the data used for this work can be obtained from the corresponding author upon reasonable request.

FUNDING:

This work received no external funding.

DECLARATION OF INTEREST:

Ahmad Sobri Muda received consulting honoraria from Philips Medical in 2021 and speaker honoraria from Balt Interventional in 2020.

REFERENCES:

1. Fiebach JB, Schellinger PD, Jansen O, Meyer M, Wilde P, Bender J, et al. CT and Diffusion-Weighted MR Imaging in Randomized Order Diffusion-Weighted Imaging Results in Higher Accuracy and Lower Interpreter Variability in the Diagnosis of Hyperacute Ischemic Stroke. *Stroke*. 2002;33(9):2206–

2210. doi: 10.1161/01.STR.0000026864.20339.CB.
2. Lansberg MG, Albers GW, Beaulieu C, Marks MP. Comparison of diffusion-weighted MRI and CT in acute stroke. *Neurology*. 2000;54(8):1557–1561. doi: 10.1212/WNL.54.8.1557.
3. Goyal M, Ospel JM, Menon B, Almekhlafi M, Jayaraman M, Fiehler J, et al. Challenging the Ischemic Core Concept in Acute Ischemic Stroke Imaging. *Stroke*. 2020;51(10):3147–3155. doi: 10.1161/STROKEAHA.120.030620.
4. Thomalla G, Simonsen CZ, Boutitie F, Andersen G, Berthezene Y, Cheng B, et al. MRI-guided thrombolysis for stroke with unknown time of onset. *New England Journal of Medicine*. 2018 Aug 16;379(7):611–22. doi: 10.1056/NEJMoa1804355
5. Sølling C, Ashkanian M, Hjort N, Gyldensted C, Andersen G, Østergaard L, et al. Feasibility and logistics of MRI before thrombolytic treatment. *Acta Neurol Scand*. 2009;120(3):143–149. doi: 10.1111/j.1600-0404.2008.01136.x.
6. Sablot D, Gaillard N, Colas C, Smadja P, Gely C, Dutray A, et al. Results of a 1-year quality-improvement process to reduce door-to-needle time in acute ischemic stroke with MRI screening. *Rev Neurol*. 2017;173(1-2):47–54. doi: 10.1016/j.neurol.2016.12.032.
7. Sablot D, Ion I, Khelifa K, Faouil G, Leibinger F, Gaillard N, et al. Target Door-to-Needle Time for Tissue Plasminogen Activator Treatment with Magnetic Resonance Imaging Screening Can Be Reduced to 45 min. *Cerebrovasc Dis*. 2018;45(5-6):245–251. doi: 10.1159/000489568.
8. Chiu LQ, Quek DYJ, Salihan RB, Ng WM, Othman RB, Lee CH, et al. ACT-FAST: a quality improvement project to increase the percentage of acute stroke patients receiving intravenous

- thrombolysis within 60 minutes of arrival at the emergency department. *Singapore Med J.* 2021;62(9):476-481. doi: 10.11622/smedj.2020040.
9. Kamal N, Shand E, Swanson R, Hill MD, Jeerakathil T, Imoukhuede O, et al. Reducing Door-to-Needle Times for Ischaemic Stroke to a Median of 30 Minutes at a Community Hospital. *Can J Neurol Sci.* 2019;46(1):51-56. doi: 10.1017/cjn.2018.368.
 10. Muda AS, Khafiz MFA, Yaakob MNM, Rahim EA, Mahmood MK, Noh MSFM et al. Putra Acute Stroke Protocol. *CVNS.* 2021;3(4):23-25. doi: 10.32896/cvns.v3n4.12-14.
 11. Sakamoto et al
Chia PK, Mohamad NA, Mat LNI, Itam@Ismail I, Khan AHKY, Loh WC, et al. Regional Emergency Stroke Quick-Response (RESQ) Network: A Proposed Paradigm of Malaysia Stroke Care Services. *Malaysian J Med Health Sci.* 2020;16(4):353-361.
 12. Macha K, Hoelter P, Siedler G, Knott M, Schwab S, Doerfler A, et al. Multimodal CT or MRI for IV thrombolysis in ischemic stroke with unknown time of onset. *Neurology.* 2020;95(22):e2954-e2964. doi: 10.1212/WNL.0000000000011059.
 13. Basri H, Puvanarajah S, Yahya WNNW, Kee HF, Aziz ZA, Ibrahim KA, et al. Clinical Practice Guidelines: Management of Ischaemic stroke. 3rd ed. 2020. *CVNS* 2021;3(1):1-155. doi: 10.32896/cvns.v3n1.1-155.

FIGURE LEGENDS:

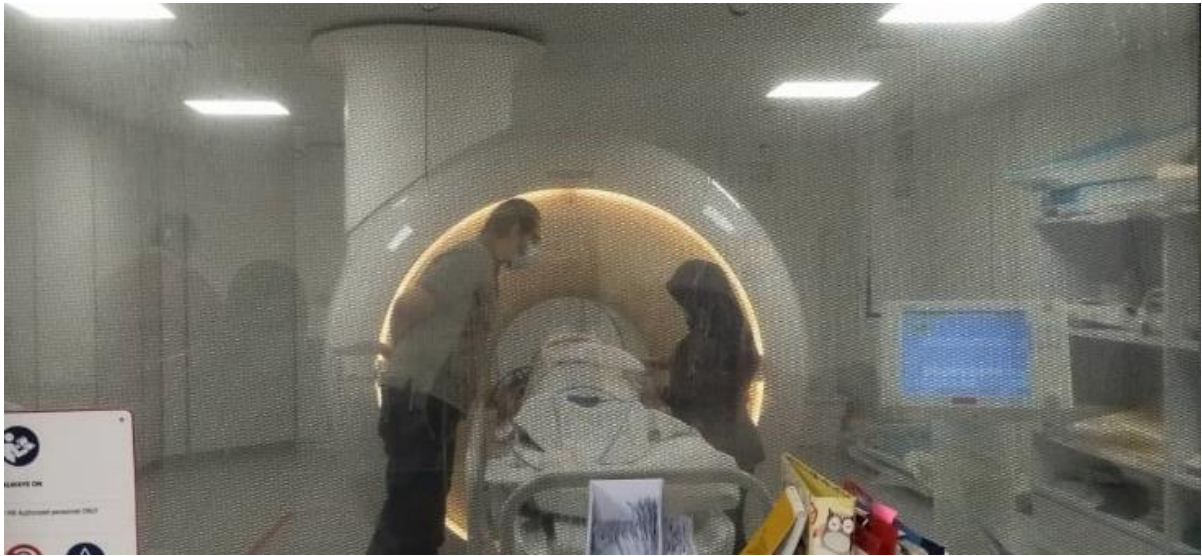

Figure 1: Thrombolysis in MR suite.

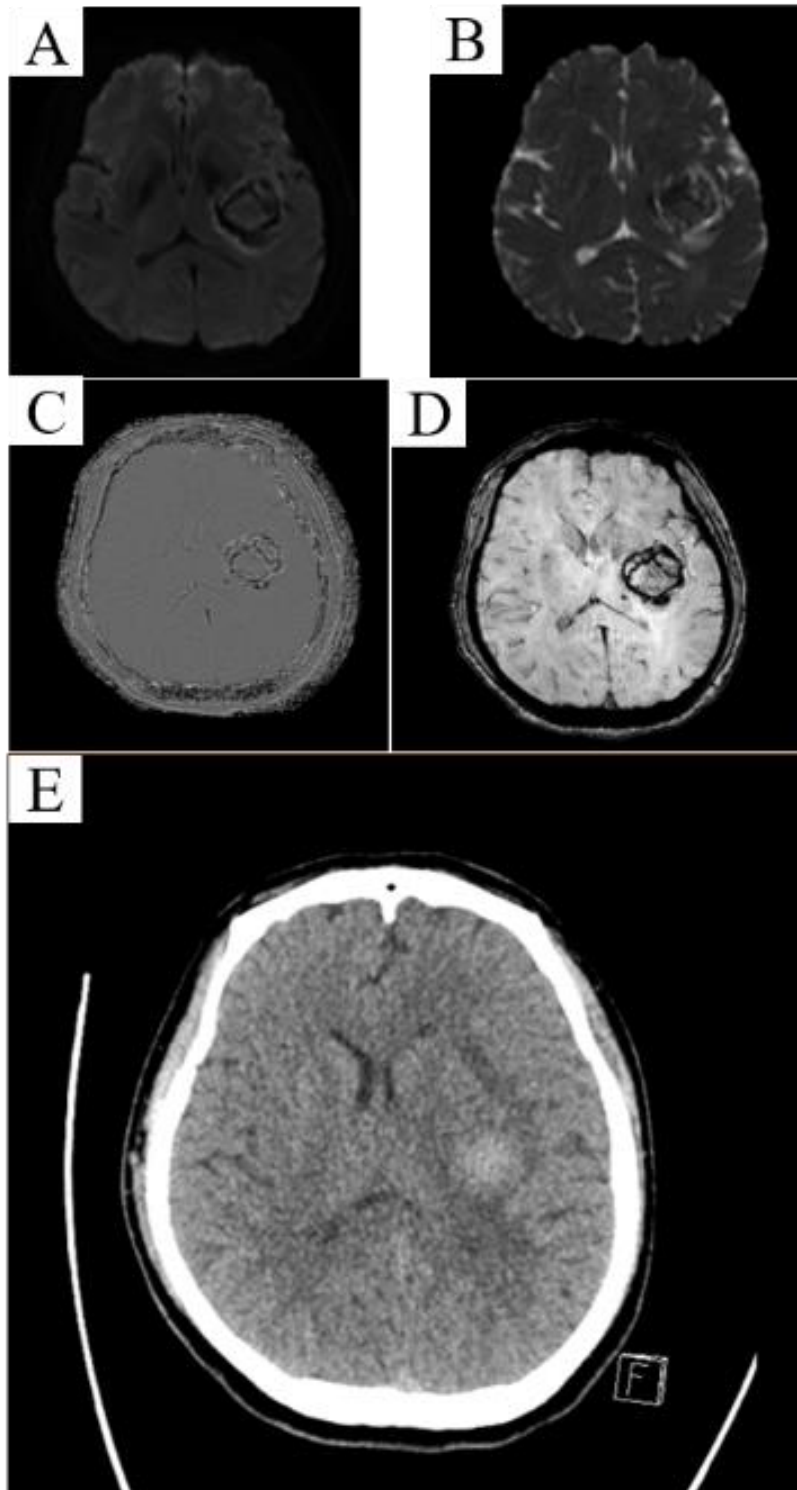


Figure 2: DWI shows area of hypointensity with surrounding hyperintensity rim (A) and corresponding Apparent Diffusion Coefficient (ADC) shows surrounding hyperintensity rim with heterogenous hypointensities centrally (B). The SWI with phase images (C, D) confirms presence of haemorrhage in the left basal ganglia. The CT scan (E) done within few hours of MRI shows presence of haemorrhage in the left basal ganglia.

TABLE LEGEND:

Table 1: Putra Acute Stroke Protocol starts with DWI, followed by FLAIR and MRA, which constitute total of 8.5 minutes (10). Then followed by other relevant sequences, without disrupting the initiation of the acute treatment. Most of the treatment decision can be achieved after the third sequence.

Sequences	Acquisition Time (min: sec)
DWI	1:47
FLAIR	2:40
MRA	4:09
SWI	3:42
Perfusion Imaging (Contrast)	2:05
Black Blood Vessel Wall Imaging	5:00
Other Sequences	